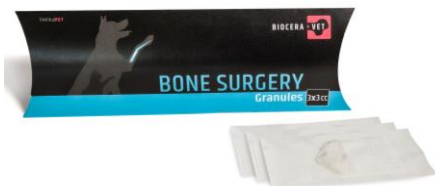

CASE STUDY

BIOCERA-VET GRANULES

The affordable biocompatible calcium-phosphate bone substitute



- **Unique composition** - Calcium deficient hydroxyapatite for an optimal osteo-integration and conduction
- **Biocompatible and resorbable synthetic bone graft**
- **Price-conscious solution** - Optimal extender to auto-and allograft procedures

Canine tooth root fracture

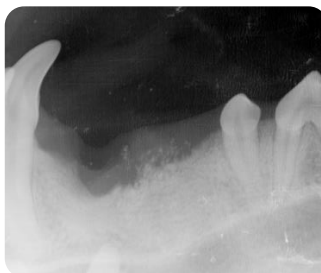
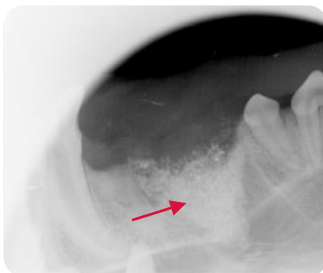
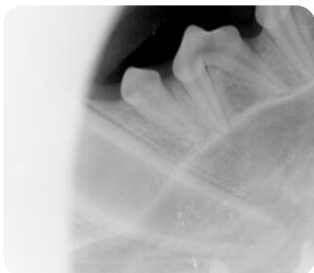
Kaizer, German Sheperd, 1-year old



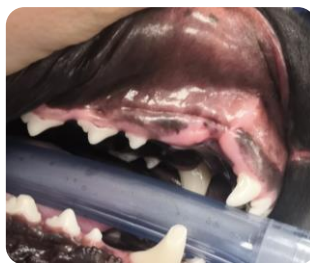
PRE-OP

POST-OP

6 Weeks POST-OP



→ BIOCERA-VET GRANULES



- **Canine tooth root fracture**
- Dental extraction performed with filling of the cavity with BIOCERA-VET Granules 1cc.
- Radiological follow-up at 6 weeks showed good bony ingrowth with advanced resorption of BIOCERA-VET Granules

Case performed by Dr. Nora Schwitzer, DVM, PhD, MRCV, MyVet Luncan, Ireland



Back to the bone

www.bioceravet.com ► customerservice@thera.vet ► © 2023 TheraVet SA

Case study Granules – ENG – Version 01 – March 2023

