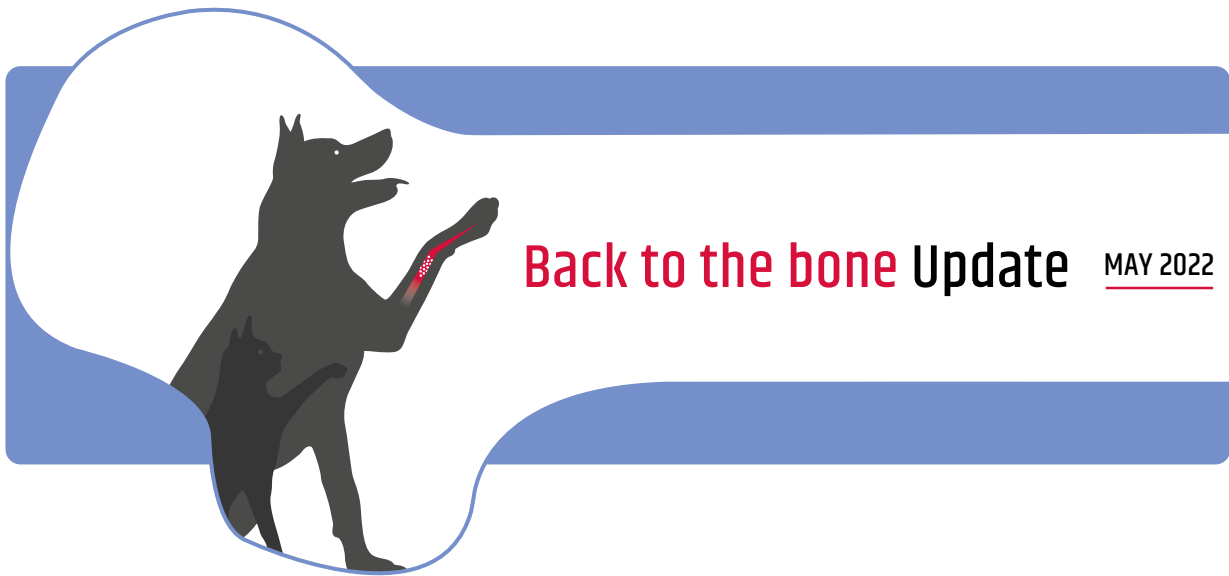



BIOCERA-VET BONE SURGERY – COMPARATIVE ANALYSIS VS. BONE AUTOGRAFT CLINICAL CASES REPORT IN THE INDICATION OF ARTHRODESIS¹

Year: 2022. Author: Céline Molle (TheraVet®). Study performed in collaboration with 11 veterinary orthopedic surgeons in France and Belgium: Dr Guillaume Ragetly ECVS, ACVS, Centre Hospitalier Vétérinaire Frégis, France; Pr Marc Balligand ECVS, Clinique Vétérinaire Universitaire de Liège, Belgium; Dr Bernard Bouvy ECVS, ACVS, Clinique Vétérinaire Universitaire de Liège, Belgium; Dr Bernard Flasse, CES in veterinary osteoarticular and traumatology surgery, Centre Vétérinaire Beumont, Belgium; Dr Olivier Stiévenart, Surgivet, Belgium; Dr Yves Samoy ECVSMR, Clinique Vétérinaire Universitaire de Gand, Belgium; Dr Johan Van Ommen, Dierenkliniek Orion, Belgium; Dr Julien Carabalona CES in veterinary osteoarticular and traumatology surgery, Clinique Vétérinaire Olliolis, France; Pr Olivier Gauthier, Oniris-Nantes, France; Dr Antoine Raffi, Clinique Vétérinaire Gaillacoise, France; Dr. Chantal Ragetly, ECVS, ACVS, Clinique Vétérinaire Evolia, France (for blind radiological assessment)

Materials & Methods

- ▶ BIOCERA-VET®¹ injectable synthetic self-hardening calcium-phosphate bone substitute
- ▶ BIOCERA-VET (n=27) vs. autograft (n=16)
- ▶ Tarsal (BIOCERA-VET: n= 10 ; autograft: n=4) and carpal (BIOCERA-VET: n=17 ; autograft: n=12) arthrodesis
- ▶ Surgical procedure and clinical follow-up according to usual practice

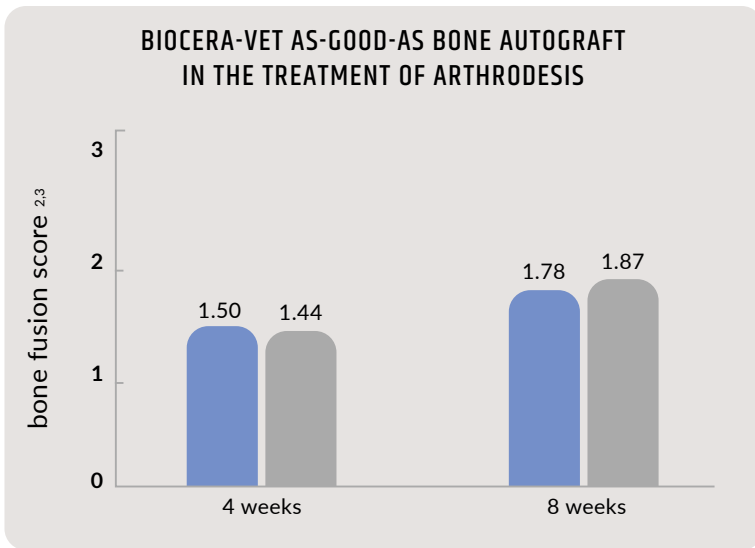
Bone fusion was assessed by following an independent blinded radiological analysis performed by a qualified orthopedic surgeon using a numerical rating scale^{2,3} rating from:

- ▶ 0: No mineralized (bone) tissue visible in the joint space;
- ▶ 1: Cancellous bone bridging the joint space, but joint space still clearly visible;
- ▶ 2: Bony bridging of joint space but subchondral bone plate still clearly visible;
- ▶ 3: Solid fusion of adjacent bones with modelling of bone and loss of subchondral bone plate.

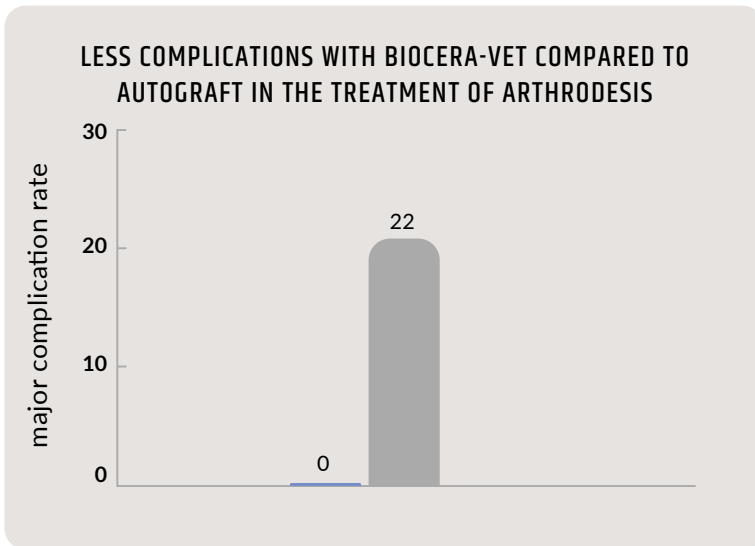
Comparative analysis was performed at 4⁴ and 8⁵ weeks post-surgery.

Results: Bone fusion induced by BIOCERA-VET was as-good-as the one induced by bone autograft.

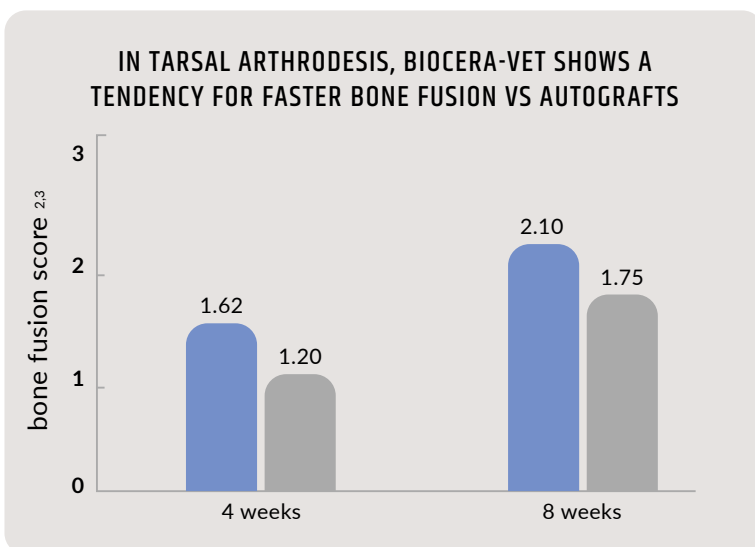
** This study was conducted with BIOCERA-VET BONE SURGERY 3cc version*



No major complications were reported in the 27 cases treated with BIOCERA-VET. The major complication rate in the cases treated with autograft was of 22%, similar to those reported in the literature, i.e. 15 to 30%^{6,7,8}.



In a smaller subgroup of pantarsal arthrodesis⁹, bone fusion induced by BIOCERA-VET was 50% more advanced than the one induced by bone autografts, although not reaching statistical significance. These observations suggest that BIOCERA-VET may accelerate the bone fusion process at tarsal level compared to autograft.





Dr. Guillaume Ragetly
DMV, PhD, Dipl. ACVS, Dipl. ECVS

Dr. Guillaume Ragetly, Head of Department of Surgery at CHV Frégis (France): "BIOCERA-VET induces bone fusion thanks to its interesting properties of osteoconduction and osteointegration. It has real advantages for the veterinary surgeon allowing him to have an alternative to autograft, with less complications while saving significant surgical time".

CONCLUSION

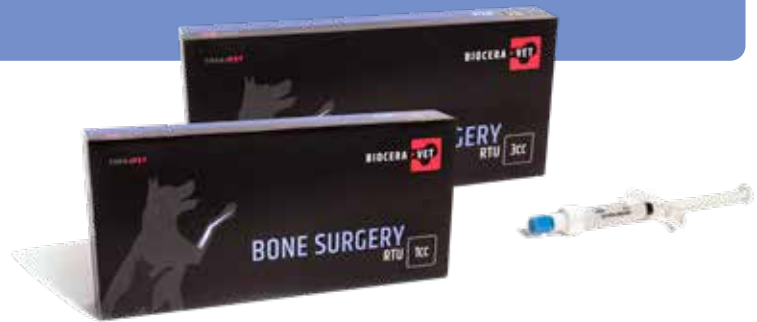- ▶ BIOCERA-VET shows a comparable efficacy to bone autograft in the treatment of arthrodesis with less complications
- ▶ In tarsal arthrodesis, BIOCERA-VET shows a tendency for faster bone fusion in comparison with autograft



BONE SURGERY RTU

Indications

- ▶ Arthrodesis
- ▶ Fractures
- ▶ Corrective osteotomy
- ▶ TTA (Tibial Tuberosity Advancement)
- ▶ All indications for which bone grafts are required



For more information and order: www.bioceravet.com

¹ Efficacy and safety assessment of a self-setting bone substitute (α -tcp) as an efficient alternative to autografts Ragetly G.R. 1, Bouvy B. 2, Flasse B. 3, Stievenart O. 4, Van Ommen J. 5, Ragetly C.A. 6 CHV Frégis, Paris, France; 2. CVU de Liège, Université de Liège, Liège, Belgium; 3. Centre Vétérinaire Univet Beumont, Wavre, Belgium; 4. Vetcare Center, Beersel, Belgium; 5. Dierenkliniek Orion, Herentals, Belgium; 6. Clinique Vétérinaire EVOLIA, L'isle-Adam, France. Best poster presentation award at WVOC/VOS 2022. ² Micharl et al., Healing of dorsal pancarpal arthrodesis in the dog. *Journal of Small Animal Practice* 2003, 44(3), 109-112. ³ Ree, JJ et al., Augmentation of arthrodesis in dogs using a free autogenous omental graft. *Can Vet J.* 2016 Aug;57(8):835-41. ⁴ Radiological evaluation performed from 3 to 5 weeks post-surgery ⁵ Radiological evaluation performed from 6 to 8 weeks post-surgery ⁶ Hoffer, MJ et al., Clinical Applications of Demineralized Bone Matrix: A Retrospective and Case-Matched Study of Seventy-Five Dogs. *Veterinary Surgery*, 2008 37(7), 639-647. ⁷ McKee, WM et al., Pantarsal arthrodesis with a customised medial or lateral bone plate in 13 dogs. *Australian Veterinary Journal*, 2004 82(12), 749-749. ⁸ Tuan, J et al., Clinical outcomes and complications of pancarpal arthrodesis stabilised with 3.5 mm/2.7 mm locking compression plates with internal additional fixation in 12 dogs. *New Zealand Veterinary Journal*, 2019 1-16. ⁹ Arthrodesis performed at tarsus